

A New Vacuum-Formed Phase I Retainer

KEVIN L. THEROUX, DDS, MS

Retention after Phase I orthodontic treatment has traditionally involved either a maxillary Hawley-type acrylic plate, with a labial bow across the permanent incisors, or a single-thickness vacuum-formed retainer. The Hawley retainer has the advantages of being rigid enough to maintain palatal expansion and durable enough to last for several years. Its rigidity also allows the operator to trim the appliance to allow for eruption of the posterior teeth.

Mechanical retention of the Hawley retainer in the mixed dentition can be difficult, however, since the first permanent molars often have short clinical crowns and little undercut at this age. Claspings of the primary molars may be effective, but exfoliation will eventually force the clinician to discontinue the appliance. Some orthodontists have resorted to leaving the maxillary first permanent molar bands in place to permit positive claspings.

Another disadvantage of the Hawley design is that the labial bow typically crosses the occlusion in the canine region. When the permanent canines erupt, the labial bow can interfere, again causing a premature end of retention. Hawley retainers also require considerable laboratory time and wire-bending skills, and are relatively

expensive.

A single-layer vacuum-formed appliance is less costly and can be made quickly in the office. Such a retainer is not rigid enough for trimming, however, and is easily broken. It may also lack sufficient rigidity to maintain palatal expansion. A laboratory-made version, the Starnes Bite Orthotic,¹ has extensions that allow it to be used in both the maxillary and mandibular arches, but is more costly and must be sent out for fabrication.

The Theroux Phase One Essix

We have used the retainer design described here as our Phase I retention appliance almost exclusively since 1998. The Theroux Phase One Essix is a modification of the retainer described in the *Essix Handbook*² (Fig. 1). A single layer of Essix* material over the permanent incisors and first molars provides positive retention of the appliance. The palatal area of the appliance is a double thickness of Essix material—rigid enough to be easily trimmed for erupting teeth,

*Raintree Essix, Inc., 4001 Division St., Metairie, LA 70002.



Fig. 1 Theroux Phase One Essix retainer.

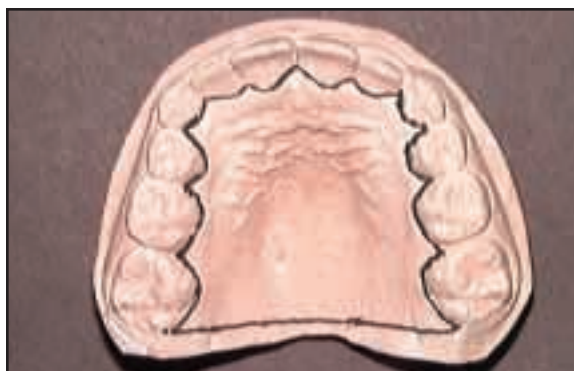

Fig. 2 Black line drawn on cast to mark first palatal layer of retainer.



Dr. Theroux is in the private practice of orthodontics at 8200 E. Belleview Ave., Suite 415E, Greenwood Village, CO 80111; e-mail: drt@drtheroux.com.

much like conventional orthodontic acrylic. There are no clasps, and no labial wire to interfere with canine eruption.

The appliance is sturdy and can be made quickly and inexpensively in the office by any clinical staff member. No wire-bending skills are necessary. In most cases, the appliance is more retentive than a Hawley or single-thickness vacuum-formed retainer.

Fabrication

The reference lines referred to below may be omitted once the operator is familiar with appliance fabrication.

1. Take an alginate impression of the maxillary arch, and pour it in Essix stone.*
2. Rough-trim the working model so it can be seated in the vacuum-forming machine. There must not be any voids in the plaster, and the entire palate must remain intact.
3. With a felt-tipped marker, draw a black line across the palate, connecting the distolingual cusps of the permanent first molars. Continue the line along the lingual gingival margins of all other teeth that are present. This will be the out-

line of the first palatal layer of the retainer (Fig. 2).

4. Lightly spray a silicone lubricant** over the cast, then vacuum-form one layer of .030" Type A Essix material.

5. Draw a green line over the Essix material, starting in the buccal vestibule adjacent to the first permanent molars, passing over to the occlusal surfaces of the primary molars and canines, crossing to the labial vestibule at the primary canines, and passing labial to the incisors (Fig. 3). This second line marks where the Essix material is cut from the cast, so that the plaster will not be altered in the area where the second layer of material will go.

6. Use an Essix wheel saw* to cut the appliance off the cast, following the green line. Remove the appliance from the model, and cut the material back with a curved crown-and-bridge scissor and an acrylic bur in a slow-speed handpiece, following the black line, so that all that remains is a single layer of material covering the palate. This piece of material should contact the lingual gingival margins of all teeth and end just distal to

*Dentsply International, Inc., 570 W. College Ave., York, PA 17405.

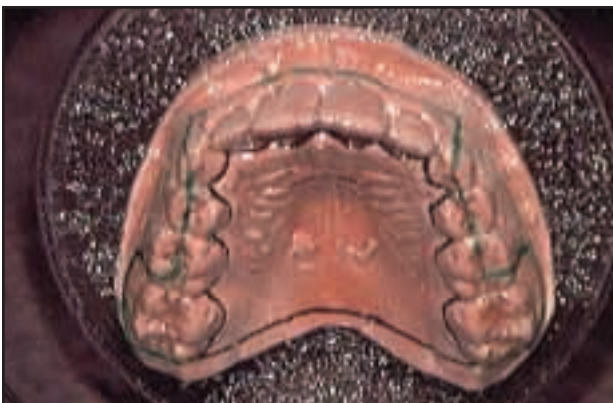

Fig. 3 Green line drawn over Essix material to mark where acrylic is cut from cast.

the first permanent molars. Place this palatal layer of Essix material back on the cast (Fig. 4).
7. Add a horseshoe-shaped arch of acrylic monomer, 3-4mm wide, over the exposed surface of the Essix material. The open end of the arch should lie adjacent to the first permanent molars, at least 3mm from the edge of the plastic. Apply a single-line bead of Triad Gel** over the acrylic monomer. If the patient wants colored glitter added to make the appliance more visible and distinctive, sprinkle the glitter over the soft Triad Gel. Light-cure the Triad material, then blow off the excess glitter (Fig. 5).

**Dentsply International, Inc., 570 W. College Ave., York, PA 17405.

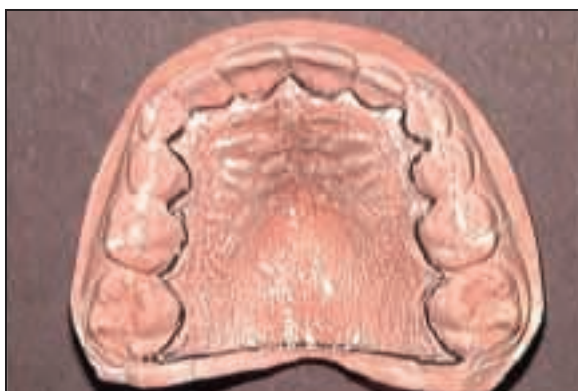

Fig. 4 Palatal layer of Essix material cut off and replaced on cast.

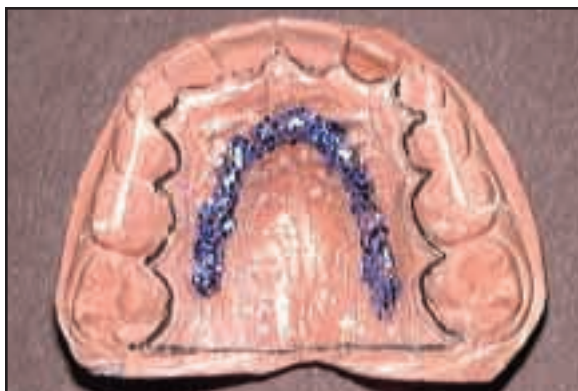


Fig. 5 Horseshoe-shaped arch of acrylic monomer and customized glitter light-cured over palatal Essix layer.

8. Place the cast with the palatal material back into the vacuum-forming machine. Lightly paint the gel/glitter with acrylic monomer, and immediately vacuum-form another sheet of Essix Type A material over the cast. A double thickness of Essix material will then cover the palate, with a single thickness over the rest of the cast (Fig. 6). Let the cast sit for 30 minutes to cure.

9. Cut the retainer from the cast, following the saw line created earlier. This will leave a single layer of material fully covering the maxillary permanent incisors and first molars and a double layer of material over the palate. While holding the retainer, use an acrylic lab bur in a slow-speed handpiece and crown-and-bridge scissors to trim the anterior material so that it covers only the incisors. Trim the material back in the palatal area so that the appliance ends at the lingual gingival margins of the primary molars—the black line drawn in Step 3.

10. No polishing is necessary; the retainer is ready to be delivered (Fig. 7). Total fabrication time is 50-60 minutes, including the 30 minutes spent waiting for the acrylic to cure.

Clinical Management

Seat the retainer in the mouth with finger pressure (Fig. 8). Show the patient how to remove it by pulling down on the incisal material.

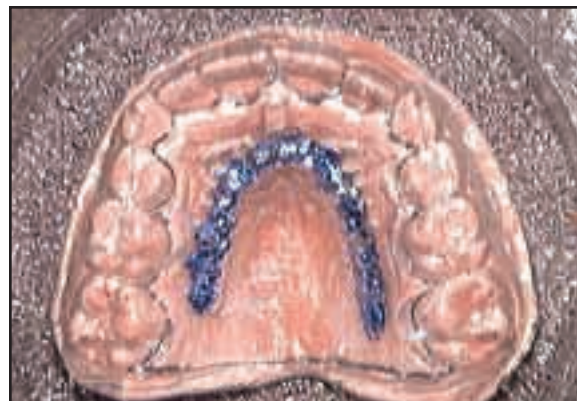

Fig. 6 Second layer of Essix material vacuum-formed over cast.

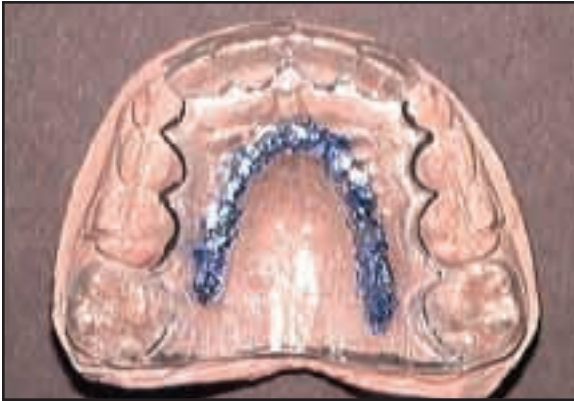

Fig. 7 Completed retainer.

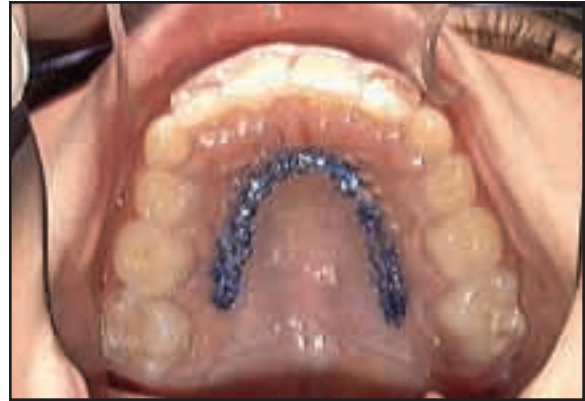

Fig. 8 Retainer seated in mouth with finger pressure.

The retainer should be worn only while sleeping, stored in a retainer case when not in the mouth, and brushed daily with toothpaste. Patients are seen at four-to-six-month intervals, and the palatal material is trimmed as necessary with an acrylic bur in a slow-speed handpiece to allow for bicuspid eruption.

One of the occlusal wings covering the first molars will occasionally break off. If this occurs, have the patient simply cut off the other wing and wear the retainer as before. I have never seen the development of an anterior open bite with this appliance. If the patient is to wear a headgear during the resting period after Phase I, the molar wings may be omitted initially.

I have seen only one case since 1998—a patient with extremely short anterior clinical crowns—where the retainer failed to stay in the mouth. In that case, a Hawley retainer with clasps to maxillary molar bands had to be made.

Conclusion

The Theroux Phase One Essix can be fabricated entirely in the office with no wire bending. It is inexpensive, secure, and durable. After Phase I orthodontic treatment, with only nighttime wear, the retainer maintains palatal expansion and incisor positions, can be adjusted for posterior dental development, and does not interfere with canine eruption.

REFERENCES

1. Starnes, L.O.: A bite orthotic for the resting period between two phases of treatment, *J. Clin. Orthod.* 36:92-94, 2002.
2. *The Essix Technology Update Manual*, Raintree Essix, Inc., Metairie, LA.